

PAEDIATRICS:

Questions-part

I

1. Most common organism associated with cystic fibrosis is
 - a. Pseudomonas aeruginosa (non mucoid)
 - b. Burkholderia cepacia
 - c. Pleisomonas
 - d. Aeromonas
2. Which of the following statement about cystic fibrosis is not true?
 - a. Autosomal recessive disorder
 - b. Abnormality in CFTR which leads to defective calcium transport
 - c. Mutation in cystic fibrosis transport regulator
 - d. The most prevalent mutation of *CFTR* is $\Delta F508$
3. All the following statements about congenital rubella are true except
 - a. IgG persists for more than 6 months
 - b. IgM antibody is present at birth
 - c. Most common anomalies are hearing and cardiac defect
 - d. Increased risk of congenital malformation if infection occurs after 16 weeks
4. A child is admitted on day 7 of life with severe respiratory distress and shock. He was discharged 2 days back healthy. What could be the probable diagnosis?
 - a. Large VSD
 - b. Hypoplastic left heart syndrome
 - c. Ebstein anomaly
 - d. AP window defect
5. Ductus dependent blood flow is required for all of these congenital heart disease except
 - a. Persistent truncus arteriosus
 - b. Hypoplastic left heart syndrome
 - c. Pulmonary stenosis
 - d. TGA with intact ventricular septum
6. Eisenmenger syndrome- true are all except
 - a. Pulmonary veins are not distended
 - b. RV and LV walls come back to normal size
 - c. Dilatation of central pulmonary artery
 - d. Peripheral pruning of pulmonary arteries
7. All are signs of impending Eisenmenger syndrome except
 - a. Increased flow murmur across tricuspid and pulmonary valve
 - b. Single S2
 - c. Loud P2
 - d. Graham steel murmur
8. An alert 6 months old child is brought with vomiting and diarrhea. RR-45/min, SBP-85mm of Hg. Capillary refilling time is 4 secs. Diagnosis is
 - a. Early compensated hypovolemic shock
 - b. Early decompensated hypovolemic shock
 - c. Late compensated hypovolemic shock
 - d. Late decompensated hypovolemic shock
9. Congenital toxoplasmosis –false is-
 - a. Diagnosed by detection of IgM in cord blood
 - b. IgA is more sensitive than IgM for detection
 - c. Dye test is gold standard for IgG
 - d. Avidity testing must be done to differentiate between IgA and IgM
10. Best indicator of growth monitoring in children
 - a. Weight
 - b. Mid-arm circumference
 - c. Rate of increase in height and weight
 - d. Head circumference
11. Which of the following is not true about new born assessment?

PAEDIATRICS:

- a. A poor APGAR score at 7 min indicates neonatal mortality
- b. Fetus can rapidly washout CO₂ through placenta
- c. Anaerobic metabolism causes acidemia
- d. A poor APGAR score at 1 min indicates need for respiratory resuscitation

12. The most common fetal response to acute hypoxia is:

- a. Tachycardia
- b. Tachypnea
- c. Bradycardia
- d. Ventricular arrhythmia

13. Which of the following intrauterine infections are associated with limb reduction defects and scarring of skin?

- a. Varicella virus
- b. Herpes virus
- c. Rubella
- d. Parvovirus

14. Which of the following agents is likely to cause cerebral calcification and hydrocephalus in a newborn whose mother has history of taking spiramycin but was not compliant with therapy?

- a. Rubella
- b. Toxoplasmosis
- c. CMV
- d. Herpes

15. 18 month old child can:

- a. Knows gender
- b. Speak 3 line sentences
- c. Make tower of 3 cubes
- d. Stands on 1 leg for 5

16. A child with recurrent chest infections and recurrent sinusitis, with dextrocardia and situs invertus. Diagnosis?

- a. Kartagenar syndrome
- b. Campbell syndrome
- c. Ehler's Danlos syndrome

d. Marfan's syndrome

17. All of the following nutritional assessment methods indicate inadequate nutrition, except

- a. Hb < 11.5 g / dl during 3rd trimester of pregnancy
- b. Increased 1-4 year mortality rate
- c. Birth weight < 2500 gm
- d. Decreased weight for height

18. Prophylaxis of a neonate born to a HBsAg positive mother should include

- a. Vaccine
- b. Immunoglobulin
- c. Both vaccine and immunoglobulin
- d. No active treatment required

19. PGE may cause worsening in an infant with

- a. Pulmonary stenosis without VSD
- b. Left hypoplastic heart syndrome
- c. Obstructive TAPVC
- d. Obstruction in aorta

20. All of the following statements about teething are true, EXCEPT:

- a. All deciduous teeth have erupted by the age of 2-3 years
- b. All upper teeth appear earlier except lower central incisors
- c. Upper central incisors are the first to appear
- d. First temporary molars erupt by 12-16 months

21. The following statement about Gomez classification is false:

- a. Based on height retardation
- b. Based on 50th centile boston standards
- c. Between 75 and 89% implies mild malnutrition
- d. This classification has prognostic value for hospitalization children

PAEDIATRICS:

22. The most common cause of short stature is

- a. Constitutional
- b. Systemic diseases
- c. Hypothyroidism
- d. Growth hormone deficiency

23. A very low birth weight preterm baby is on ventilator for respiratory distress. Baby presents with clinical features of necrotizing enterocolitis with perforation. What is appropriate management?

- a. Conservative management
- b. Immediate laparotomy
- c. Extra corporeal membrane oxygenation with surgery after stabilization
- d. Peritoneal drainage

24. Probiotics have been found beneficial for use in

- a. Necrotizing enterocolitis
- b. Neonatal sepsis
- c. Candidiasis
- d. Intestinal perforation

25. *In case of breath holding spell:*

- a. *Ignore the child*
- b. *Avoid precipitating factors*
- c. *Admit the child to the hospital, preferably NICU*
- d. *Treat depending on the degree to which the child turns blue*

26. Right sided aortic arch is most strongly / commonly associated with

- a. Tetralogy of Fallot (TOF)
- b. Ventricular septal defect (VSD) with pulmonary atresia
- c. Corrected TGA
- d. Truncus arteriosus

27. All of the following statements about Patent Ductus arteriosus (PDA) are true except

- a. It is more common in males than females
- b. It is a common heart lesion in rubella
- c. Treatment is closure of defect by ligation and division of ductus
- d. Hypoxia and immaturity are important in maintaining the patency

28. A child presented with severe respiratory distress two days after birth. On examination he was observed to have a scaphoid abdomen and decreased breath sounds on the left side. He was managed by prompt endotracheal intubation. After ET tube placement the maximal cardiac impulse shifted further to the right side. What should be the next step in management?

- a. Confirm the position of endotracheal tube by chest X ray
- b. Remove tube and reattempt intubation
- c. Nasogastric tube insertion & decompress the bowel
- d. Chest X ray to confirm diagnosis

29. A child presented with severe respiratory distress two days after birth. On examination he was observed to have a scaphoid abdomen and decreased breath sounds on the left side. He was managed by prompt endotracheal intubation. After ET tube placement the maximal cardiac impulse shifted further to the right side. What should be the next step in management?

- a. Confirm the position of endotracheal tube by chest X ray
- b. Emergency surgery
- c. Nasogastric tube insertion & decompress the bowel
- d. Chest X ray to confirm diagnosis

30. A neonate has recurrent attacks of abdominal pain, restless, irritability and diaphoresis on feeding. Cardiac auscultation reveals a nonspecific murmur. He is

PAEDIATRICS:

believed to be at risk for MI. Likely diagnosis is:

- a. Anomalous coronary artery
- b. VSD
- c. TOF
- d. ASD

31. A male born at term after an uncomplicated pregnancy, labor and delivery develops severe respiratory distress within a few hours of birth. Results of routine culture were negative. The chest roentgenogram reveals a normal heart shadow and fine reticulonodular infiltrates radiating from the hilum. ECHO findings reveal no abnormality. Family history reveals similar clinical course and death of a male and female sibling at 1 month and 2 months of age respectively. The most likely diagnosis is

- a. Neonatal alveolar proteinosis
- b. Total anomalous pulmonary venous circulation (TAPVC)
- c. Meconium aspiration syndrome
- d. Diffuse herpes simplex infection

32. Commonest type of seizure in newborn

- a. Clonic
- b. Tonic
- c. Subtle
- d. Myoclonic

33. Symptomatic neonatal CNS involvement is most commonly seen in which group of congenital intrauterine infections

- a. CMV and toxoplasmosis
- b. Rubella and toxoplasmosis
- c. Rubella and HSV
- d. CMV and syphilis

34. CNS involvement is most commonly associated with which group of congenital intrauterine infections

- a. CMV and toxoplasmosis
- b. Rubella and toxoplasmosis
- c. Rubella and HSV

d. CMV and syphilis

35. A patient presents with LVH and pulmonary complications. ECG shows left axis deviation. Most likely diagnosis is:

- a. TOF
- b. TAPVC
- c. Tricuspid atresia
- d. VSD

36. Resistant plasmodium falciparum malaria in the pediatric age group should be treated by

- a. Chloroquine
- b. Tetracycline
- c. Clindamycin
- d. Doxycycline

37. Which of the following vaccines has maximum efficacy after a single dose?

- a. Tetanus toxoid
- b. DPT
- c. Measles
- d. Typhoid

38. A new born presents with congestive heart failure. O/e bulging fontanelle with bruit on auscultation. Transfontanelle USG shows hypoechoic midline mass with dilated lateral ventricles. Diagnosis:

- a. Medulloblastoma
- b. Encephalocele
- c. Vein of Glen malformation
- d. Arachnoid cyst

39. Which condition is most commonly associated with coarctation of aorta?

- a. PDA
- b. Bicuspid aortic valve
- c. Aortic stenosis
- d. VSD

40. A 7 ½ months old child with cough, mild stridor is started on oral antibiotics. The child showed initial improvement but later developed wheeze, productive cough, and

PAEDIATRICS:

mild fever. X –ray shows hyperlucency and PFT shows on obstructive curve. The most probable diagnosis is:

- a. Bronchiolitis obliterans
- b. Post viral syndrome
- c. Pulmonary alveolar microlithiasis
- d. Follicular bronchitis

41. Amongst various treatment modalities for nocturnal enuresis, the relapse rates have been observed to be lowest for

- a. Desmopressin
- b. Imipramine
- c. Bell alarm systems
- d. Oxybutinin

42. Most sensitive indicator of depletion of intravascular volume in infants is:

- a. Heart rate
- b. Cardiac output
- c. Stroke volume
- d. Blood pressure

43. Which of the following will favour the diagnosis of RDS in new born?

- a. Receipt of antenatal steroids
- b. Manifests after 6 hrs
- c. Air bronchogram in chest X-ray
- d. Occurs after term gestation

44. a premature baby, born at 33 weeks of gestation with a birth weight of 1500 gms has stable vitals . Which of the following is the initial feeding method of choice?

- a. Intravenous fluids
- b. Intravenous fluids and oral feeding
- c. Total parenteral nutrition
- d. Orogastric tube/ alternate oral route

45. Which of the following drugs are used in a patient of tetralogy of fallot?

- a. Digoxin, furosemide and oxygen
- b. Morphine, soda bicarb and propranolol
- c. Atenolol and D.C converter

d. Captopril and Aminophylline

46. A 10 yr old child is always restless, inattentive to study and always wants to play outside. Parents are extremely distressed.

What would you advise?

- a. It is a normal behaviour
- b. Behavior therapy
- c. It is a serious illness requires medical treatment
- d. Needs change in environment

47. A 2 yr old child is brought to emergency at 3 am with fever, barking cough and stridor only while crying. The child was able to drink normally. On examination, respiratory rate is 36 / min and temperature is 39.6C. What will be your next step?

- a. Racemic epinephrine nebulisation
- b. Dexamethasone
- c. Nasal wash for influenza or respiratory syncytial virus
- d. Antibiotics and blood culture

48. Most common cause of seizure in newborn is

- a. Hypoxia induced ischemic encephalopathy
- b. Hypocalcemia
- c. Metabolic abnormality
- d. Sepsis

49. A baby has recently developed mouthing but has not developed stranger anxiety, likes and dislikes for food. What is the most appropriate age of this baby?

- a. 3 months
- b. 5 months
- c. 7 months
- d. 9 months

50. Following are the components of APGAR score expect?

- a. Color
- b. Muscle tone
- c. Heart rate

PAEDIATRICS:

- d. Respiratory rate
51. Which of the following milestones develops first?
- Mirror play
 - Crawling
 - Creeping
 - Pincer grasp
52. A 32 wk new born baby with RR-86/min, grunting present with no nasal flaring, abdomen behind in movement than chest, minimum intercostals retraction and no xiphisternal retraction. What is the silverman scoring?
- 4
 - 1
 - 3
 - 6
53. Moro's reflex disappears at
- 3 months
 - 5 months
 - 6 months
 - 7 months
54. Which of the following reflexes is not present at birth?
- Asymmetric tonic neck reflex
 - Moro's reflex
 - Symmetric tonic neck reflex
 - Crossed extensor reflex
55. Child with PDA will not have
- CO₂ wash out
 - Bounding pulses
 - Necrotising enterocolitis
 - Pulmonary hemorrhage
56. Which of the following is the best indicator of long term nutritional status?
- Mid arm circumference
 - Height for age
 - Weight for age
 - Weight for height
57. Which of the following is a minor criteria for diagnosis of Rheumatic fever (RF) according to modified Jones criteria?
- ASO titre
 - Past history of rheumatic fever
 - Fever
 - Subcutaneous nodules
58. Which of the following is a component of pentalogy of fallot
- Atrial septal defect (ASD)
 - Patent ductus arteriosus (PDA)
 - Coarctation of aorta (COA)
 - Left ventricular hypertrophy (LVH)
59. Most common mode of treatment of a 1 year old child with asthma is
- Inhaled short acting beta 2 agonist
 - Oral short acting theophylline
 - Oral ketotifen
 - Leukotriene agonist
60. The leukotriene receptor antagonist used in bronchial asthma is
- Zafireleukast
 - Zileuton
 - Ketotifen
 - Omalizumab
61. A child with three days history of upper respiratory tract infection presents with stridor, which decreases on lying down position. What is the most probable diagnosis?
- Acute epiglottitis
 - Laryngotracheobronchitis
 - Foreign body aspiration
 - Retropharyngeal abscess
62. A neonate has ABO incompatibility. Peripheral smear will show
- Microspherocytes
 - Elliptocytes
 - Fragmented RBCs
 - Polychromophilia

PAEDIATRICS:

63. Jitteriness can be distinguished from seizures by all of the following except
- Sensitivity to stimulus
 - Frequency of movement
 - Abnormality of Gaze
 - Autonomic disturbance
64. Premature baby of 34 weeks was delivered. Baby developed bullous lesion on the skin and X-ray shows periostitis. What should be the next investigation?
- VDRL for mother & baby
 - Elisa for HIV
 - PCR for TB
 - Hepatitis surface antigen for mother
65. A girl child with fever, cough, dyspnoea with x-ray showing right lower lobe patchy consolidation, for which treatment was given. After 8 weeks symptom improved but x-ray showed more dense consolidation involving the whole of the right lower lobe. What is the next best line of investigation?
- Bronchoscopy
 - Culture from nasopharynx
 - Barium esophagogram
 - Allergic skin test
66. 4 year old boy presented with recurrent chest infections. Sweat chloride test was done, showed values of 36 and 42. what is the next best investigation to confirm the diagnosis?
- 72 hour fecal fat estimation
 - CT chest
 - Trans epithelial nasal potential difference
 - DNA analysis of delta F 508 mutation
67. Which vaccine is contraindicated in child with history of convulsion?
- DPT
 - Measles
 - Typhoid
 - BCG
68. National immunization programme, all are involved except
- TT
 - Hepatitis B
 - OPV
 - Measles
69. 18 months old child, who has received one dose of DPT and OPV at 2 months of age. What will be your next immunization plan?
- Restart immunization schedule, as per age
 - Measles, BCG, booster dose of DPT and OPV
 - Measles, booster dose of DPT and OPV
 - BCG, 2nd dose of DPT and OPV
70. Pondreal index of baby with weight of 2000gm and length of 50 cm is
- 2.2
 - 2.6
 - 1.6
 - 3.6
71. Vigorous MSL, all are true except
- Good respiratory efforts
 - heart rate > 100
 - tracheal Suctioning of meconium is done under direct vision using laryngoscope.
 - good muscle tone
72. 2 days after birth, child developed respiratory distress and had scaphoid abdomen. Breath sounds were decreased on the left side. After bag and mask ventilation, ET tube was put and the maximal cardiac impulse shifted to the right side. What should be the next step in management?
- Confirm the position of endotracheal tube
 - Emergency surgery

PAEDIATRICS:

- c. Naso gastric tube insertion
d. Chest x-ray
73. Regarding polio which is true
- Most of the cases are symptomatic
 - Spastic paralysis is seen
 - IM injections and increased muscular activity increases the risk of paralytic polio
 - Pulse polio immunization is indicated in all children less than 3 years of age
74. Essential criteria for TOF includes all except?
- Valvular stenosis
 - Infundibular stenosis
 - Over riding of aorta
 - RVH
75. Following will favour the diagnosis of RDS in new born except?
- Almost always in preterm babies often < 34 weeks of gestation
 - Shake test negative
 - Lecithin: Spingomylin (L: S) ratio < 2
 - Air bronchogram in chest X-ray
76. Persistence of Moro's reflex is abnormal beyond the age of
- 3rd month
 - 4th month
 - 5th month
 - 6th month
77. A 3 year old boy with normal developmental milestones with delayed speech and difficulty in communication and concentration. He is not making friends. Most probable diagnosis is
- Autism
 - ADHD
 - Mental retardation
 - Specific learning disability
78. Most common cause of neonatal sepsis in hospital in India is
- Escherichia coli
 - Klebsiella
 - Staph aureus
 - Listeria monocytogen
79. A term neonate with unconjugated hyperbilirubinemia of 18 mg/dl on 20th day. All are common causes except
- Breast milk jaundice
 - Congenital cholangiopathy
 - G 6PD deficiency
 - Hypothyroidism
80. How will a staff nurse prepare Normal saline from 10% Dextrose (per 100 ml)?
- 20 ml 10% D with 80 ml NS
 - 60 ml 10% D with 40 ml NS
 - 60 ml 10% D with 40 ml NS
 - 80 ml 10% D with 20 ml NS
81. Drug of choice for rheumatic fever prophylaxis in pencillin allergic patient
- Erythromycin
 - Clindamycin
 - Vancomycin
 - Gentamycin
82. Common to both acute and chornic malnutrition is
- Weight for age
 - Weight for height
 - Height for age
 - BMI
83. True about cow's milk are all except
- Cow's milk contains 80% whey protein not casein
 - Cow milk has less carbohydrate than mothers milk
 - Has more K⁺ and Na⁺ than infant formula feeds
 - Has more protein than breast milk
84. A 6 years child with IQ of 50. Which of the following can the child do

PAEDIATRICS:

- a. Identify colours
 - b. Read a sentence
 - c. Ride a bicycle
 - d. Copy a triangle
85. A normally developing 10 month old child should be able to do all of the following except
- a. Stand alone
 - b. Play peek a boo
 - c. Pick up a pellet with thumb and index finger
 - d. Build a tower of 3-4 cubes
86. A child is below the third percentile for height. His growth velocity is normal, but chronologic age is more than skeletal age. The most likely diagnosis is:
- a. Constitutional delay in growth
 - b. Genetic short stature
 - c. Primordial dwarfism
 - d. Hypopituitarism
87. All of the following are feature of prematurity in a neonate, except
- a. No creases on sole
 - b. Abundant lanugo
 - c. Thick ear cartilage
 - d. Empty scrotum
88. Which of the following is the principal mode of heat exchange in an infant incubator?
- a. Radiation
 - b. Evaporation
 - c. Convection
 - d. Conduction
89. The following are characteristic of autism except
- a. Onset after 6 years of age
 - b. Repetitive behavior
 - c. Delayed *language* development
 - d. Severe deficit in social interaction
90. Which of the following malformation in a newborn is specific for maternal insulin dependent diabetes mellitus?
- a. Transportation of great arteries
 - b. Caudal regression
 - c. Holoprosencephaly
 - d. Meningocele
91. The requirement of potassium in a child is
- a. 1-2 mEq/kg
 - b. 4-7 mEq/kg
 - c. 10-12 mEq/kg
 - d. 13-14 mEq/kg
92. The sodium content of ReSoMal (rehydration solution for malnourished children) is:
- a. 90 mmol/L
 - b. 60 mmol/L
 - c. 45 mmol/L
 - d. 30 mmol/L
93. The most common etiological agent for acute bronchiolitis in infancy is:
- a. Influenza virus
 - b. Para influenza virus
 - c. Rhinovirus
 - d. Respiratory syncytial virus
94. The following features are true for tetralogy of Fallot, except
- a. Ventricular septal defect
 - b. Right ventricular hypertrophy
 - c. Atrial septal defect
 - d. Pulmonary stenosis
95. Blalock and Taussig shunt is done between:
- a. Aorta to pulmonary artery
 - b. Aorta to pulmonary vein
 - c. Subclavian artery to pulmonary vein
 - d. Subclavian vein to artery
96. In which of the following conditions left atrium is not enlarged:

PAEDIATRICS:

- | | |
|---|-------|
| a. Ventricular septal defect | 5. A |
| b. Atrial septal defect | 6. B |
| c. Aortopulmonary window | 7. B |
| d. Patent ductus arteriosus | 8. A |
| 97. A 1-month-old boy is referred for failure to thrive. On examination, he shows feature of congestive failure. The femoral pulses are feeble as compared to brachial pulses. The most likely clinical diagnosis is: | 9. D |
| a. Congenital aortic stenosis | 10. C |
| b. Coarctation of aorta | 11. B |
| c. Patent ductus arteriosus | 12. C |
| d. Congenital aortoiliac disease | 13. A |
| 98. A 30 week gestation mother delivered 1.2 kg baby with moderate respiratory distress (RR-70/min with grunting and chest retraction). Most logical next step is | 14. B |
| a. Warm humidified oxygen via hood | 15. C |
| b. Surfactant and mechanical ventilation | 16. A |
| c. Nasal CPAP | 17. A |
| d. Mechanical ventilation | 18. C |
| 99. All the following can occur in a neonate for heat production except | 19. C |
| a. Shivering | 20. C |
| b. Breakdown of brownfat with adrenaline secretion | 21. A |
| c. Universal flexion like a fetus | 22. A |
| d. Cutaneous vasoconstriction | 23. D |
| 100. The important fatty acid present in breast milk which is important for growth is | 24. A |
| a. Docosahexaenoic acid | 25. B |
| b. Palmitic acid | 26. D |
| c. Linoleic acid | 27. A |
| d. Linolenic acid | 28. B |

Answers paper part

- | | |
|------|-------|
| I | 29. C |
| 1. A | 30. A |
| 2. B | 31. A |
| 3. D | 32. C |
| 4. B | 33. C |
| | 34. A |
| | 35. C |
| | 36. C |
| | 37. C |
| | 38. C |
| | 39. B |

PAEDIATRICS:

- | | |
|-------|--------|
| 40. A | 75. B |
| 41. C | 76. D |
| 42. A | 77. A |
| 43. C | 78. B |
| 44. D | 79. B |
| 45. B | 80. D |
| 46. B | 81. A |
| 47. B | 82. A |
| 48. A | 83. A |
| 49. B | 84. A |
| 50. D | 85. D |
| 51. A | 86. A |
| 52. A | 87. C |
| 53. A | 88. C |
| 54. C | 89. A |
| 55. A | 90. B |
| 56. B | 91. A |
| 57. C | 92. C |
| 58. A | 93. D |
| 59. A | 94. C |
| 60. A | 95. A |
| 61. B | 96. B |
| 62. A | 97. B |
| 63. B | 98. C |
| 64. A | 99. A |
| 65. A | 100. A |
| 66. C | |
| 67. A | |
| 68. B | |
| 69. D | |
| 70. C | |
| 71. C | |
| 72. A | |
| 73. C | |
| 74. A | |

PAEDIATRICS:

Questions-

part II

1. Which of the following is the earliest indicator of pathological gastroesophageal reflux in infants (GERD)?

- a. respiratory symptoms
- b. postprandial regurgitation
- c. upper GI bleed
- d. stricture esophagus

2. A previously healthy infant presents with recurrent episodes of abdominal pain. The mother says that the child has been passing altered stool after episodes of pain, but gives no history of vomiting or bleeding per rectum. Which of the following is the most likely diagnosis?

- a. rectal polyps
- b. intussusception
- c. meckel's diverticulum
- d. necrotizing enterocolitis

3. Which of the following is the most common tumor associated with Monocytosis and increased Fetal Hb in a child

a. juvenile myelomonocytic leukemia (JMML)

b. acute lymphoblastic leukemia (ALL)

- c. acute myeloid leukemia (AML)
- d. chronic myeloid leukemia (CML)

4. A one year old child presents with short stature, lethargy, and constipation. Clinical examination shows a palpable goiter. Laboratory investigations revealed a low T4 and elevated TSH which of the following is the most likely diagnosis

- a. thyroid dysmorphogenesis
- b. thyroid dysgenesis

- c. central hypothyroidism
- d. TSH receptor blocking antibody

5. An 8 days old infant is brought to the emergency department with vomiting, lethargy, dehydration and features of shock. Clinical examination reveals hyperpigmentation of the genital skin and normal external genitalia. Abdominal examination is unremarkable. Blood tests revealed sodium of 124 meq/l and hypoglycemia. Which of the following is the most likely diagnosis?

- a. congenital adrenal hyperplasia(CAH)
- b. adrenal haemorrhage
- c. acute gastroenteritis with dehydration
- d. hyperaldosteronism

6. a 15 day old baby presented to the emergency department with history of seizures. Blood tests revealed serum calcium of 5mg/dl, serum phosphate of 9 mg/dl and an intact PTH of 30 pg/ml (normal intact PTH= 10-60pg/ml). Which of the following is the most likely diagnosis?

- a. pseudohypoparathyroidism
- b. hypoparathyroidism
- c. vitamin D Deficiency
- d. hypoxic ischemic encephalopathy

7. A child presents with recurrent bouts of severe cough followed by an audible whoop. Which of the following is considered the best type of specimen to isolate the organism and confirm the diagnosis?

- a. nasopharyngeal swab
- b. cough plate
- c. throat swabs
- d. anterior nasal swab

PAEDIATRICS:

8. A previously healthy eight year old boy presented to the emergency department with high grade fever, arthralgia,, pruritic erythematous rash and lymphadenopathy. He has completed 8 days out of 10 day course of cefaclor for an upper respiratory tract infection. Which of the following possibilities should be initially suspected?

- a. Kawasaki disease
- b. anaphylaxis
- c. henoch schonlein purpura
- d. type III hypersensitivity reaction

9. Left sided isomerism is associated with

- a. polysplenia
- b. one spleen
- c. two spleens
- d. asplenia

10. A 9 year old boy has steroid dependent nephrotic syndrome for the last 5 year. The patient is markedly cushingoid with blood pressure of 120/86 mmHg and small subcapsular cataracts. The most appropriate therapy of choice is-

- a. Long term furosemide with enalapril
- b. Cyclophosphamide
- c. Intravenous immunoglobulin
- d. Intravenous pulse corticosteroids

11. A child with acute myeloid leukemia presents with hypeleukocytosis.

Treatment includes all of the following except

- a. Adequate hydration
- b. Allopurinol
- c. Rasburicase
- d. Acidification of urine

12. All of the following are true about childhood polycystic kidney disease, except

- a. Pulmonary hypoplasia not seen
- b. Autosomal recessive
- c. Renal cysts are present at birth
- d. Congenital hepatic fibrosis may be seen

13. A 7 year old girl is brought with complaints of generalized swelling of the body. Urinary examination reveals Grade 3 proteinuria and the presence of hyaline and fatty casts. She has no history of hematuria. Which of the following statements about her conditions is true?

- a. No IgG deposits or C3 deposition on renal biopsy
- b. Her C3 levels will be low
- c. IgA nephropathy is the likely diagnosis
- d. Alport's syndrome is the likely diagnosis

14. All are true about Down's syndrome except?

- a. In translocation, if mother is carrier then recurrence is 5%.
- b. Trisomy of 21st chromosome occur in 95 % cases
- c. majority of translocations are Robertsonian translocation
- d. If balanced translocation then recurrence is 100%.

15. A 6yr old child with bleeding history with petechial hemorrhages. Fever with TLC-60,000/mm³, total platelet 20,000/mm³, Hb-9.1, flow cytometry : CD10+, MPO+, CD117+, CD19+, CD33-, CD3-

- a. ALL
- b. AML
- c. Multilineage leukemia

PAEDIATRICS:

- d. Undifferentiated leukemia
16. A 7 day old infant with leaking meningomyelocele. The most useful test for diagnosis and management is:
- a. blood c/s (culture sensitivity)
 - b. urine c/s
 - c. rectal swab c/s
 - d. wound swab c/s
17. A five year old boy presents with precocious puberty and a blood pressure of 130/80mm Hg. Estimation of which of the following will help in diagnosis
- a. \uparrow 17 hydroxy progesterone
 - b. \uparrow Cortisol
 - c. \uparrow Aldosterone
 - d. \uparrow 11 deoxycortisol
18. Which of the following is not a feature of juvenile idiopathic arthritis?
- a. Spikes of high fever
 - b. Uveitis
 - c. Evanescent maculopapular rash
 - d. Rheumatoid nodules is seen in all types
19. Which of the following statements about neuroblastoma is true?
- a. Lung metastasis are common
 - b. Less than 50 % present with metastasis at time of diagnosis
 - c. Most common extracranial solid tumor in childhood
 - d. do not encase aorta and its branches at time of diagnosis
20. Which of the following is true about neural tube defects markers in amniotic fluid?
- a. \uparrow Acetylcholinesterase and \downarrow α fetoprotein
 - b. \uparrow Pseudocholinesterase and \uparrow Acetylcholinesterase
 - c. \uparrow Acetylcholinesterase and \uparrow α fetoprotein
 - d. \uparrow Butyrylcholinesterase and \uparrow α fetoprotein
21. A child presents with massive hepatomegaly and hypoglycemia. There is no improvement in blood glucose on administration of Glucagon. The probable diagnosis is:
- a. Von Gierke disease
 - b. McArdle disease
 - c. Cori's disease
 - d. Forbe's disease
22. A 6 yr child presents with recurrent episodes of gross hematuria for 2 yrs. He is likely to have:
- a. IgA nephropathy
 - b. Wilm's tumour
 - c. Henoch schonlein purpura (HSP)
 - d. Neuroblastoma
23. All the following statements regarding Kawasaki disease are true except?
- a. It is the most common cause of vasculitis in children
 - b. IV immunoglobulins are recommended for treatment.
 - c. Associated with coronary artery aneurysm in up to 25% of untreated cases
 - d. Unilateral cervical lymph node enlargement > 1.5 cm.
24. Which of the following statement about 21 alpha hydroxylase deficiency is false:

PAEDIATRICS:

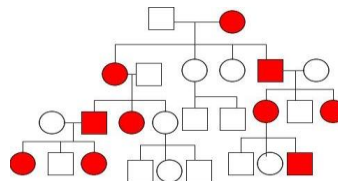
- a. Most common cause of congenital adrenal hyperplasia (CAH) in children
 - b. Affected females present with ambiguous genitalia
 - c. Hyperkalemic acidosis is seen
 - d. Affected males present with ambiguous genitalia
25. Which of the following statements about cerebellar astrocytomas in pediatric age group is false?
- a. These are usually low grade tumors
 - b. These tumors have a good prognosis
 - c. These are more commonly seen in the 1st and 2nd decades
 - d. These tumours are more common in females
26. What is the probable diagnosis for a cyst in a child which is located at and associated with vertebral defects?
- a. Myelocele
 - b. Bronchogenic cyst
 - c. Neuroenteric cyst
 - d. Neuroblastoma
27. a 3-month old infant presents with bilateral medullary nephrocalcinosis. All of the following can cause medullary nephrocalcinosis except
- a. Hyperoxaluria
 - b. Bartter's syndrome
 - c. Prolonged use of furosemide
 - d. ARPKD
28. A 10-month old baby previously normal suddenly becomes distressed in his crib. The external appearance of genitalia was normal, except hyperpigmentation. Blood glucose showed a level of 30mg%. What is the most probable diagnosis?
- a. 21 hydroxylase deficiency
 - b. Hyperinsulinism
 - c. Familial glucocorticoid deficiency
 - d. Cushing's syndrome
29. A child presents with hepatosplenomegaly, abdominal distension, jaundice, anemia and adrenal calcification, which of the following is the diagnosis?
- a. Adrenal hemorrhage
 - b. Wolman's disease
 - c. Pheochromocytoma
 - d. Addison's disease
30. A 3-month old male child with normal genitalia presents to the emergency department with severe dehydration, hyperkalemia and hyponatremia. The measurement blood levels of which of the following will be helpful?
- a. 17-hydroxy progesterone
 - b. Renin
 - c. Cortisol
 - d. Aldosterone
31. A child develops non-blanching macules and papules on lower extremities, mild abdominal pain and skin biopsy showed IgA deposition. Most appropriate diagnosis is-
- a. Drug induced vasculitis
 - b. HSP
 - c. Wegener's granulomatosis
 - d. Kawasaki disease
32. Which of the following drugs is used for the treatment of refractory histiocytosis?
- a. High dose methotrexate
 - b. High dose cytarabine

PAEDIATRICS:

- c. 2-chlorodeoxyadenosine
d. Fludrabine
33. Most common inherited childhood tumor is
- Leukemia
 - Neuroblastoma
 - Retinoblastoma
 - Wilm's tumor
34. Absent thumb, radial deviation of wrist, bowing of forearm with thrombocytopenia which investigation needs not to be done?
- Echocardiography
 - Bone marrow examination
 - Platelet count
 - Karyotyping
35. Macrocephaly is seen in all of the following except
- Metachromatic leucodystrophy
 - Alexander disease
 - Krabbe's disease
 - Canavan's disease
36. Turner syndrome is maximally associated with
- Horseshoe kidney
 - Coarctation of aorta
 - VSD
 - ASD
37. A infant with Hypertonia, Elongated skull (prominent occiput), microcephaly, Rocker-bottom feet, and closed fists with overlapping of digits defect is suffering from
- Trisomy 21
 - Trisomy 13
 - Trisomy 18
 - Turner
38. Type of AML associated with chloromas or granulocytic sarcomas are seen typically in.
- M₂
 - M₃
 - M₅
 - M₇
39. All of the following syndromes are associated with AML except
- Down's syndrome
 - Klinefelter's syndrome
 - Patau syndrome
 - Turner's syndrome
40. All of the following are good prognostic factors for childhood leukemia. All except
- Hyperdiploidy
 - Female sex
 - Pre B cell ALL
 - T (12:21) translocation
41. Cardiomyopathy is not a feature of
- Duchenne's muscular dystrophy
 - Friedreich's ataxia
 - Pompe disease
 - Lowe's syndrome
42. Most common organism causing meningitis in a 1 year old child
- Streptococcus pneumoniae
 - H. influenza
 - Listeria
 - Neisseria meningitides
43. A child has microcephaly, blue eyes, fair skin, and mental retardation, ferric chloride test is positive. What is the likely diagnosis?
- Phenylketonuria (PKU)
 - Homocystinuria
 - Tyrosinosis

PAEDIATRICS:

- d. Alkaptonuria
44. Darkening of urine on standing is associated with?
- Alkaptonuria
 - Cystinuria
 - Fabry's disease
 - Tyrosinemia
45. A child is brought with drowsiness, decreased deep tendon reflexes and seizures. On examination the child has a line on gums. There is history of constipation. Which will be most appropriate drug that should be used in this child?
- EDTA
 - DMSA
 - BAL
 - Pencillamine
46. A infant with cleft lip, cleft palate, polydactyl, microcephaly with holoprosencephaly, ectodermal scalp defect is suffering from
- trisomy 18
 - trisomy 21
 - trisomy 22
 - trisomy 13
47. All of the following are included in quadruple test for screening of Down's syndrome except
- Increased PAPP A
 - Increased inhibin A
 - decreased α -fetoprotein
 - Increased free beta HCG levels
48. Deep white matter lesion with bilateral deep bright thalamic appearance is suggestive of
- Alexander disease
 - Canavan's diseases
 - Krabbe's disease
- d. Metachromatic leukodystrophy
49. A 8 year old male had non blanching rashes over the shin and swelling of knee joint with haematuria +++ and protein + . Microscopic analysis of his renal biopsy specimen is most likely to show.
- Tubular necrosis
 - Visceral podocyte fusion
 - Mesangial deposits of IgA
 - Basement membrane thickening
50. All of the following conditions have autosomal dominant inheritance except
- Duchenne muscular dystrophy
 - Marfan's syndrome
 - Osteogenesis imperfecta
 - Ehlers danlos syndrome
51. In an autosomal recessive (AR) disorder, one parent is normal and the other is carrier and the child is also affected. What is the reason?
- Germ line mosaicism
 - Genomic imprinting
 - Penetration
 - Uniparental disomy
52. Pedigree analysis- analyze the following pedigree and give the mode of inheritance



- Autosomal recessive
- Autosomal dominant
- Mitochondrial inheritance
- X linked dominant

PAEDIATRICS:

53. Baby born at 30 weeks for 18 year old primi gravida of weight 2 kg which died after 48 hours. Apgar scores were 5 and 8 at 1 and 5 minutes. On autopsy bilateral enlarged kidney with multiple radially arranged cysts. Which of the following finding is expected to be associated with?
- Imperforate anus
 - Hepatic cyst and fibrosis
 - Absence of ureter
 - Holoprosencephaly
54. myopathy is seen in all except
- x-linked hypophosphatemic rickets
 - oncogenic osteomalacia
 - nutritional osteomalacia
 - cushing syndrome
55. Most common cause of renal artery stenosis in children in India is
- Takayasu aortoarteritis
 - Fibromedial hypertrophy
 - Fibrointimal hyperplasia
 - Polyarteritis nodosa
56. A newborn baby presented with profuse bleeding from umbilical stump after birth. Probable diagnosis is
- Factor XIII deficiency
 - VWF deficiency
 - Factor XII deficiency
 - Glanzmann thrombosthenia
57. A 5 year old boy comes with overnight petechial spots 2 weeks back he had history of abdominal pain and no hepatosplenomegaly. Diagnosis is
- Acute lymphatic leukemia
 - Aplastic anemia
 - Idiopathic thrombocytopenic purpura
 - Acute viral infection
58. All of the following may occur in Down's syndrome except
- Hypothyroidism
 - Undescended testis
 - Ventricular septal defect
 - Brushfield's spots
59. The earliest indicator of response after starting iron in a 6-year-old girl with iron deficiency is
- Erythroid hyperplasia
 - Increased reticulocyte count
 - Increased hemoglobin
 - Increased ferritin
60. Late onset hemorrhagic disease of newborn is characterized by all of the following fetures except
- Usually occurs in cow-milk fed babies
 - Onset occurs at 4-12 week of age
 - Intracranial hemorrhage can occur
 - Intramuscular vitamin K prophylaxis at birth has a protective role
61. the most important determinant of prognosis in wilms tumor
- Stage of disease
 - Loss of heterozygosity of chromosome 1p
 - Histology
 - Age less than one year at presentation
62. A malignant tumor of childhood that metastasizes to bones most often is
- Wilm's tumor
 - Neuroblastoma
 - Adrenal gland tumors

PAEDIATRICS:

- d. Granulose cell tumor of ovary
63. The process underlying differences in expression of a gene, according to which parent has transmitted, is called
- Anticipation
 - Mosaicism
 - Non-penetrance
 - Genomic imprinting
64. A child with a small head, minor anomalies of the face including a thin upper lip, growth delay, and developmental disability can have all of the following, except
- A chromosomal syndrome
 - A teratogenic syndrome
 - A mendelian syndrome
 - A polygenic syndrome
65. An affected male infant born to normal parents could be an example of all of the following except
- An autosomal dominant disorder
 - An autosomal recessive disorder
 - A polygenic disorder
 - A vertically transmitted disorder
66. In a family, the father has widely spaced eyes, increased facial hair and deafness. One of the three children has deafness with similar facial features. The mother is normal. Which one of the following is most likely pattern of inheritance in this case?
- Autosomal dominant
 - Autosomal recessive
 - X-linked dominant
 - X-linked recessive
67. The coagulation profile in a 13-year old girl with Menorrhagia having von Willebrand disease is:
- Isolated prolonged PTT with a normal PT.
 - Isolated prolonged PT with a normal PTT.
 - Prolongation of both PT and PTT.
 - Prolongation of thrombin time.
68. Single gene defect causing multiple unrelated problems
- Pleiotropism
 - Pseudodominance
 - Penetrance
 - Anticipation
69. In SCHWARTZ formula for calculation of creatinine clearance in a child, the constant depends on the following except
- Age
 - Method of estimation of creatinine
 - Mass
 - Severity of renal failure
70. Which organ is the primary site of hematopoiesis in the fetus before midpregnancy?
- Bone
 - Liver
 - Spleen
 - Lung
71. A 3-year-old boy presents with fever, dysuria and gross hematuria. Physical examination shows a prominent suprapubic area which is dull on percussion. Urinalysis reveals red blood cells but no proteinuria. Which of the following is the most likely diagnosis?
- Acute glomerulonephritis
 - Urinary tract infection
 - Posterior urethral valves
 - Teratoma

PAEDIATRICS:

72. Enzyme replacement therapy is available for which of the following disorders?

- Gaucher disease
- Niemann pick disease
- Mucopolidosis
- Metachromatic leukodystrophy

73. All of the following are true of β thalassemia major, except

- Splenomegaly
- Target cells on peripheral smear
- Microcytic hypochromic anemia
- Increased osmotic fragility

74. Which of the following haemoglobin (Hb) estimation will be diagnostically helpful in a case of beta thalassemia trait?

- Hb-F
- Hb₁-C
- Hb-A₂
- Hb-H

75. Which one of the following is the characteristic feature of juvenile myoclonic epilepsy?

- Myoclonic seizures frequently occur in morning
- Complete remission is common
- Response to anticonvulsants is poor
- Associated absence seizures are present in majority of patients

76. A 15-year-old female presented to the emergency department with history of recurrent epistaxis, hematuria and hematochezia. There was a history of profuse bleeding from the umbilicus stump at birth. Previous investigations revealed normal prothrombin time, activated partial thromboplastin time, thrombin time and fibrinogen levels. Her

platelet counts as well as platelet function tests were normal but urea clot lysis test was positive. Which one of the following clotting factor is most likely to be deficient?

- Factor X
- Factor XI
- Factor XII
- Factor XIII

77. Barts hydrops fetalis is lethal because

- Hb Bart's cannot bind oxygen
- The excess α -globin form insoluble precipitates
- Hb Bart's cannot release oxygen to fetal tissues
- Microcytic red cells become trapped in the placenta

78. Which of the following is generally not seen in idiopathic thrombocytopenic purpura (ITP)?

- Palpable splenomegaly
- Petechiae, ecchymosis and bleeding
- More common in females
- Increased megakaryocytes in bone marrow

79. The most common leukocytoclastic vasculitis affecting children is

- Takayasu disease
- Mucocutaneous lymph node syndrome (Kawasaki disease)
- Henoch schonelin purpura
- Polyarteritis nodosa

80. Diagnosis of beta thalassemia is established by

- Nestroft test
- Hb A1 C estimation
- Hb electrophoresis
- Target cells in peripheral smear

PAEDIATRICS:

81. Which of the following is the most common renal cystic disease in infants is?

- a. Polycystic kidney
- b. Simple renal cyst
- c. Unilateral renal dysplasia
- d. Calyceal cyst

82. A child with recurrent urinary tract infections is most likely to show

- a. Posterior urethral valves
- b. Vesicoureteric reflux
- c. Neurogenic bladder
- d. Renal and ureteric calculi

83. Most common cause of renal scarring in a 3 year old child is

- a. Trauma
- b. Tuberculosis
- c. Vesicoureteral reflux induced pyelonephritis
- d. Interstitial nephritis

84. In a child, non-functioning kidney is best diagnosed by

- a. Ultrasonography
- b. IVU
- c. DTPA renogram
- d. Creatinine clearance

85. Most common presentation of a child with Wilms' tumor is:

- a. As asymptomatic abdominal mass
- b. Haematuria
- c. Hypertension
- d. Hemoptysis due to pulmonary secondary

86. Most common malignant neoplasm of infancy is:

- a. Malignant teratoma

- b. Neuroblastoma
- c. Wilm's tumor
- d. Hepatoblastoma

87. Which one of the following is the common cause of congenital hydrocephalus is?

- a. Craniosynostosis
- b. Intra uterine meningitis
- c. Aqueductal stenosis
- d. Malformations of great vein of galen

88. The following bacteria are most often associated with acute neonatal meningitis except

- a. Escherichia coli
- b. Streptococcus agalactiae
- c. Neisseria meningitidis
- d. Listeria monocytogenes

89. Blood specimen for neonatal thyroid screening is obtained on

- a. Cord blood
- b. 24 hours after birth
- c. 48 hours after birth
- d. 72 hours after birth

90. Which one of the following drugs is used for fetal therapy of congenital adrenal hyperplasia?

- a. Hydrocortisone
- b. Prednisolone
- c. Fludrocortisone
- d. Dexamethasone

91. The karyotype of a patient with androgen insensitivity syndrome is

- a. 46XX
- b. 46XY
- c. 47XXY
- d. 45X0

PAEDIATRICS:

92. At what gestation does the switchover from fetal to adult hemoglobin synthesis begin

- a. 30 weeks
- b. 36 weeks
- c. 7 days postnatal
- d. 3 weeks postnatal

93. A 2 month old girl has failure to thrive, polyuria and medullary nephrocalcinosis affecting both kidneys. Investigations show blood pH 7.48, bicarbonate 25 mEq/l, potassium 2 mEq/l, sodium 126 mEq/l and chloride 88 mEq/l. The most likely diagnosis is-

- a. Distal renal tubular acidosis
- b. Bartter syndrome
- c. Primary hyperaldosteronism
- d. Pseudohypoaldosteronism

94. A child presents with diarrhea and peripheral circulatory failure. The arterial pH is 7.0, PCO₂ 15 mmHg, and PO₂, 76 mm Hg. What will be the most appropriate therapy

- a. Sodium bicarbonate infusion
- b. Bolus of ringers lactate
- c. Bolus of hydroxyethyl starch
- d. 5% dextrose infusion

95. A 5 year old child is rushed to casualty reportedly electrocuted while playing in a park. The child is apneic and is ventilated with bag and mask. There are burns on each hand. What will be the next step in the management

- a. Check pulses
- b. Start chest compressions
- c. Intubate
- d. Check oxygen saturation

96. The treatment of choice for primary grade V vesicoureteric reflux involving both kidneys in a 6-month old boy is

- a. Antibiotic prophylaxis
- b. Ureteric reimplantation
- c. Cystoscopy followed by subureteric injection of Teflon
- d. Bilateral ureterostomies

97. An 8 day old breast fed baby presents with vomiting, poor feeding and loose stools. On examination the heart rate is 190/minute, blood pressure 50/30 mm Hg, respiratory rate 72 breaths/minute and capillary refill time of 4 seconds. Investigations show hemoglobin level of 15g/dl, Na 120 mEq/l, K 6.8 mEq/l, bicarbonate 15 mEq/l, urea 30 mg/dL and creatinine 0.6 mg/dL. The most likely diagnosis is-

- a. Congenital adrenal hyperplasia
- b. Acute tubular necrosis
- c. Congenital hypertrophic pyloric stenosis
- d. Galactosemia

98. A male infant presented with distension of abdomen shortly after birth with passing of less meconium. Subsequently a full-thickness biopsy of the rectum was performed. The rectal biopsy is likely to show-

- a. Fibrosis of submucosa
- b. Lack of ganglion cells
- c. Thickened muscularis propria
- d. Hyalinization of the muscular coat

99. A neonate is being investigated for jaundice. A liver biopsy shows features of "Giant Cell/Neonatal hepatitis". Which one of the following conditions usually results in this case?

- a. Congenital hepatic fibrosis
- b. Hemochromatosis
- c. Alpha-1-antitrypsin deficiency
- d. Glycogen storage disease Type

PAEDIATRICS:

100. A 3 year old boy has bilateral renal calculi secondary to idiopathic hypercalciuria. The dietary management includes all of the following except-

- a. Increased water intake
- b. Low sodium diet
- c. Reduced calcium intake
- d. Avoidance of meat proteins

Answers

1. B
2. B
3. A
4. A
5. A
6. A
7. A
8. D
9. A
10. B
11. D
12. A
13. A
14. A
15. C
16. D
17. D
18. D
19. C
20. C
21. A
22. A
23. A
24. D
25. D
26. D
27. D
28. C
29. B
30. A
31. B

32. C
33. C
34. A
35. C
36. B
37. C
38. A
39. D
40. C
41. D
42. A
43. A
44. A
45. A
46. D
47. A
48. C
49. C
50. A
51. D
52. D
53. B
54. A
55. A
56. A
57. C
58. B
59. A
60. A
61. C
62. B
63. D
64. D
65. A
66. A
67. A
68. A
69. D
70. B
71. C
72. A
73. D

PAEDIATRICS:

- 74. C
- 75. A
- 76. D
- 77. C
- 78. A
- 79. C
- 80. C
- 81. C
- 82. B
- 83. C
- 84. C
- 85. A
- 86. B
- 87. C
- 88. C
- 89. A
- 90. D
- 91. B
- 92. B
- 93. B
- 94. B
- 95. A
- 96. A
- 97. A
- 98. B
- 99. C
- 100. C